



Repair of Adult Hypospadias Under Local Anesthesia: The Technique and Outcomes

Lokal Anestezi Altında Adult Hipospadias Onarımı: Teknik ve Sonuçlar

Lokal Anesteziyle Erişkin Hipospadias Onarımı / Adult Hypospadias Under Local Anesthesia

Mehmet Kalkan¹, Sadi Turkan², Coşkun Şahin¹

¹Fatih University, School of Medicine, Department of Urology, Istanbul,

²Kastamonu Anadolu Hospital, Kastamonu, Turkey

Özet

Amaç: Bu klinik çalışmada; distal hipospadiası olan erişkin olgularda lokal anestezi ile hipospadias onarım tekniği ve sonuçları sunuldu. **Gereç ve Yöntem:** 2000-2010 yılları arasında yaşları 20 ile 24 (Ort.: 21.3) arasında değişen 24 olguda lokal anestezi ile hipospadias onarımı yapıldı. Hipospadias tipi 11 olguda koronal, 13 olguda subkoronal idi. Tüm olgular sünnetli idi. Tüm olgularda tübülerize insize plate üretroplasti (TIPU) tekniği uygulandı. Anestezik madde olarak penis köküne cilt altına prilocain hidroklorür 20 mg/ml, üretra içerisine % 2 lidocain içeren 12,5 g. Jel kullanıldı. Olgular Görsel ağrı skalası ile ağrı yönünden kayıt edildi. Olgular ağrı, lokal anestezinin komplikasyonları, operasyon süresi, erken ve geç komplikasyonlar yönünden değerlendirildi. **Bulgular:** Tüm olgular operasyonu kolay tolere ettiler. Peroperatif visüel ağrı skalası (VAS) ortalama 2,04 (0-4) olarak bulundu. Operasyon süresi 16 ile 35 dakika (Ort.: 24 dk.) idi. Bir olguda operasyon sırasında senkop gelişti. 3 olguda üretral fistül gelişti. Fistüller lokal anestezi ile kateter kullanmaksızın outpatient olarak onarıldı. Meatal darlık, kötü kozmetik görünüm gözlenmedi. **Tartışma:** Lokal anestezi ile TIPU tarzı hipospadias onarımının erişkin distal hipospadiaslı olgularda kabul edilebilir ağrı ile birlikte güvenli uygulanabilir olduğu gösterildi.

Anahtar Kelimeler

Erişkin; Hypospadias; Lokal Anestezi; Teknik; Visual Analog Ağrı Skalası

Abstract

Aim: In this study, we evaluated the outcomes of a hypospadias repair technique using local anesthesia in adult patients with distal hypospadias. **Material and Method:** Hypospadias repair was performed under local anesthesia in 24 cases of circumcised males from 2000–2010. The type of hypospadias was coronal in 11 cases and subcoronal in 13 cases. Tubularised incised-plate urethroplasty method was used in all of the patients. Subcutaneous prilocaine hydrochloride was administered into the root of the penis and 12.5 g of a gel containing 2% lidocaine was administered into the urethra as an anesthetic agent. The patients' pain levels were assessed using the Visual Analogue Scale (VAS). Patients were evaluated in terms of pain level, duration of the operation, and early and late complications. **Results:** All patients easily tolerated the operation, with a mean postoperative VAS pain assessment of 2.04 (0-4). The duration of the operation ranged between 16 and 35 min. One of the patients developed syncope during the operation. Urethral fistula was seen in three patients. No incidence of meatal stenosis or poor cosmetic appearance was observed. **Discussion:** Hypospadias repair under local anesthesia was demonstrated to be safely practicable with an acceptable degree of postsurgical pain in adult patients with distal hypospadias.

Keywords

Adult, Hypospadias; Local Anesthesia; Technique; Visual Analog Pain Scale

DOI: 10.4328/JCAM.2068

Received: 28.09.2013 Accepted: 23.10.2013 Printed: 01.07.2015 J Clin Anal Med 2015;6(4): 410-3

Corresponding Author: Mehmet Kalkan, Fatih Üniversitesi Tıp Fakültesi Hastanesi, Sahil Yolu Sok. No: 16, 34844 Dragos, Maltepe, İstanbul, Turkey.

T.: +905322650917 F.: +90 2163528359 E-Mail: mkalkan@fatih.edu.tr

Introduction

Hypospadias, that is a meatus opening on the ventral side of penis, is a congenital anomaly with an incidence of 3%. Hypospadias repair before the age of one year has been frequently reported in the medical literature [1]. The optimal time of hypospadias repair should be under age of one year old, but primary hypospadias cases may be encountered in adults. The used methods of anesthesia have been standardized for childhood; whereas experiences in local anesthesia in hypospadias repair in adults are limited [2]. General or regional anesthesia can be preferred in adults. It was reported that local anesthesia in minor penile surgery in adult patients is highly efficient and safe (99.5%) [3]. It has been reported that many urological endoscopic procedures are made under local anesthesia in adult. [4]. However, reports of hypospadias repair under local anesthesia could not be found in the literature. In this study, technical aspects and outcomes of hypospadias repair under local anesthesia were evaluated in cases of circumcised adult males with distal hypospadias.

Material and Method

Hypospadias surgery repair was performed under local anesthesia in 24 circumcised males with distal hypospadias who were performing compulsory military service between 2000 and 2010. Data of the patients was collected from patient charts. The type of hypospadias was coronal in 11 cases and subcoronal in 13 cases. Patients with chordee deformity, those who had undergone previous operations, and those having psychiatric diagnoses such as panic attacks or anxiety were excluded from the study. The patients were preoperatively informed about the advantages and disadvantages of local anesthesia. All the patients were informed about the results of the surgical procedure and we had a written informed consent of them.

Preparation and anesthetic technique: A cream containing a local anesthetic agent (Emla Krem®, Astra Zeneca, Istanbul, Turkey; 25 mg prilocaine/g, 25 mg lidocaine/g) was applied to the penile skin at the injection site one hour before the operation. Sedation was achieved using 2 mg midazolam (Dormicum 5 mg/5mL ampule®, Roche, Swiss) administered intravenously 30 min before the procedure and in cases of insufficient sedation, an additional 2 mg of midazolam was administered at the time of the surgery. Ramsey sedation score of 2 or 3 was targeted in all patients. All patients were monitored with SpO₂, EKG, non-invasive sphygmomanometer. An intravenous line was inserted in all patients before and during transport to the operating room. Preoperative preparation of the patients and the theater conditions were suitable to a possible intervention of the anesthesiologist. The operating table was placed in the Trendelenburg position at a 15° angle and 20 cc of local anesthetic solution [12 mL prilocaine HCl (2% Citanest®, Astra Zeneca) and 8 mL normal saline] was circumferentially injected into the subdermal area at the penile root. Surface area was taken into account to determine the dose of local anesthetics. 5 mL of gel containing 2% lidocaine (Cathejell®, Montavit, Absam/Tyrol, Austria) was given into the urethra, and then, a Foley catheter (16 French) was inserted into the bladder. Surgery was started approximately 5 minutes after local anesthesia and after checking the pain by local stimulus.

Two hours after the operation (average timing 2.5-3 hours later than application of midazolam) at the time that we know the effect of midazolam is completely relieved. The patients' pain levels were evaluated using the VAS. The patients were asked to score their postoperative pain on a 0–10 scale, with 0 representing no pain and 10 representing severe pain.

Surgical technique: After anesthetization of the penile skin using a penile block and the urethra with lidocaine gel, 2/0 sling silk suture was put into the glandular tissue. A tourniquet was applied only in 14 patients for 12–15 min. A U-shaped incision was made according to the method described by Snodgrass, and both glandular wings were created. A complete circumferential incision was not necessary, since a partial circumcision of 1-2 cm along the sides was deemed sufficient. It was used a figure six suture for configuration of the meatus for both a cosmetically proper and stenosis free meatus (Figure 1). The penis was wrapped with an elastic bandage. The bandage was removed. Patients were sent home on the second postoperative day. The urethral Foley catheter was withdrawn after 5–9 days. Postoperative analgesia was maintained with Voltaren® (Diclofenac sodium, Novartis, Swiss). We did not apply any procedures to prevent erection in our patients. Follow-up visits were conducted with patients for 1–11 (median 5,2) months to monitor possible effects of local anesthesia, meatal stenosis, cosmetic appearance, and urethral fistula.

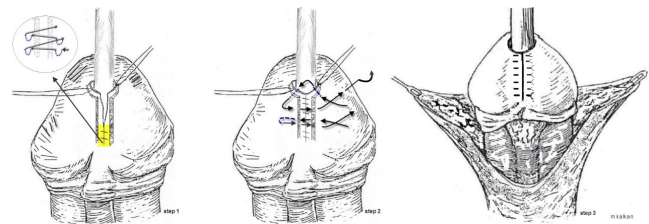


Figure 1. A technique of six suture for configuration of the meatus.

Results

The patients' ages ranged from 20–24 years (mean age: 21,3). The surgery was completed in all patients without the need for administration of general anesthesia. The sedation state was carefully monitored in each case to ensure adequate pain control during the operation, with most patients reporting only minimal discomfort during the peroperative delivery of a catheter into the bladder. No pain caused by surgical manipulation was reported, either during the insertion of the glandular sling sutures or during any subsequent stage of the operation. One patient developed hypotension during the procedure, which was resolved by bringing the operating table more to the Trendelenburg position and administering intravenous fluid replacement. The duration of the operation ranged from 16–35 min (mean operation time: 24 min). The mean postoperative VAS was 2.04 (range 0-4).

No complications caused by the local anesthetic agents were observed during the operations, and complete penile block was achieved in all cases. There was no pain by means of penile block. The operation was completed with comfort.

Nocturnal erection occurred in some cases, but did not pose a problem. None of the patients developed meatal stenosis. Cosmetic results with the original meatus in the center of the split

glans were achieved in all patients. Three patients (12,5%) developed urethral fistulas. In those patients who developed fistulae, the fistulas occurred at the site of the former meatus, and were 1, 2, and 4 mm in diameter. The fistulas were repaired under local anesthesia and without a catheter in the third (1 case) and fifth (2 cases) months. The patients having fistula repair were sent home at the same day of procedure. Demographic distribution of the patients is seen in Table 1.

Table 1. Demographic distribution of the patients

n= 24	coronal	subcoronal
	11	13
Age	21.3 (20 – 24) years	
Weight	71,3 (60-92) kg	
Preoperative preparation	Local anesthetic cream to the root of the penis and arounda	
Intravenous 2 mg midazolamb		
Local anesthetic	20 cc local anesthetic solution to the root of the penis and around c	
2% lidocaine gel to the urethrad		
Operation duration	24 (16 – 35) minutes	
Peroperative heart rate (beats min.)	110±20	
Systolic arterial blood pressure	118±42 mmHg	
SpO2	98±2%	
VAS	2,04 (0-4)	
Hospitalization time	2 days	
Catheterization duration	5-9 days	
Complication	3(2 subcoronal, 1 coronal) (12,5%) urethral fistulae	

a25 mg prilocaine/gram, 25 mg lidocaine/gram, Emla krem® Astra Zeneca
bDormicum 5 mg/5ml ampül® Deva, Turkey
c12 ml prilocaine HCl (%2 Citanest® Astra Zeneca) + 8 ml normal saline]
dCathegel® Montavit-Austria
efistula repair under local anesthesia

Discussion

Debate about the appropriate age for hypospadias repair has largely been ended by a recommendation from the American Academy of Pediatrics. The consensus recommendation of urologists and pediatricians is that 6–12 months postpartum is the most desirable period for hypospadias repair considering the potential negative effects of genital surgery on children [1]. General anesthesia with endotracheal intubation is an anesthetic method of choice for many surgical interventions. This method ensures an uninterrupted, painless, and stable anesthesia. Some studies also report application of caudal anesthesia for management of postoperative discomfort [5, 6]. Experience with hypospadias repair in adults is generally limited in developed countries [7]. However, hypospadias repair is frequently performed during adulthood in developing countries as a result of difficult economic and social conditions [8, 9]. Because of the presence of the foreskin and proximity to the meatus to the glans, parents might not consider this situation as a problem. The parents typically do not recognize a need to seek treatment and these cases may undergo circumcision since they are accepted as normal. All of our patients were over 20 years old and had been circumcised. The patients were performing compulsory military service and presented to relevant military hospitals for treatment of distal hypospadias. Repair under local anesthesia may be pre-

ferred in suitable cases because some patients prefer not to undergo general anesthesia, concerned about potential complications contributing to increased need for specialist consultations, full hospital admissions, and increased clinic workloads. Previously published techniques recommend a local penile block performed at the end of the surgery for improved management of postoperative pain [5, 10]. It is known that local anesthesia can be effectively and safely applied in minor penis surgeries in adults such as circumcision, short frenulum plasty, meatotomy, fulguration of penile or meatal warts [3]. However, the use of local anesthesia for hypospadias surgery has not been reported in literature. Our study is distinct in the use of local anesthesia in a more complicated surgery and the additional use of sedation. Several crucial details must be considered with respect to hypospadias repair under local anesthesia. While midazolam was useful in some cases, it caused uncontrolled movements (movements of limbs and willing to talk) during the surgery in others. Those movements were controlled by the belts of the table and they had no effects on the operation. It is important to give detailed information before the operation. What we mean by preoperative detailed information is detecting those patients who had operation fear and preferring local anesthesia for them. Intravenous cannula was inserted with administration of isotonic infusion before the procedure and the operating table should be in the Trendelenburg position at an angle of 15° to prevent the possibility of anxiety-related syncope. One patient developed a hypotensive condition (systolic: 70 mm Hg, pulse 54 beats/min), which we suspect may have resulted from anxiety or as an effect of a sedative agent. The condition was resolved by taking a short break in the procedure and increasing the Trendelenburg angle of the table. Mean postoperative VAS was 2.04. Patients did not experience pain when no tension was applied to the catheter during the surgical repair. Postoperative VAS scoring was performed at the time of complete relief of the effect of midazolam (average timing is 2.5-3 hours after the application). The Foley catheter was inserted into the bladder after placement of the sling suture and application of anesthetic gel to the urethra. None of the patients reported pain during the delivery of the catheter into the urethra and only minimal discomfort was observed as the catheter was advanced from the posterior urethra to the bladder. The primary disadvantages of adult hypospadias repair are late tissue healing, the possibility of infection caused by genital secretions, and nocturnal erections. However, adult hypospadias repair has also some advantages, including elimination of the need for optical magnification, reduced difficulty of working with a larger penis, hormonal stimulation is unnecessary, and the option of performing the operation and repairing any postoperative complications (e.g., fistula, meatal stenosis) under local anesthesia [11]. Urethral fistulas were seen in three patients at the former meatal localization. We thought that thin and weak skin at the proximal anastomosis site may have play a role in developing fistulas [12]. We think that the follow-up period is too short (5,2 months) to adequately assess the risk of developing meatal stenosis.

Conclusion: Despite the small number of cases, we have successfully demonstrated that hypospadias repair under local anesthesia can provide a safe and comfortable option if general or regional anesthesia is not desired due to potential complications.

Competing interests

The authors declare that they have no competing interests.

References

1. Retik AB, Borer JG. Hypospadias in Campbell's urology. In: Walsh PC, Retik AB, Vaughan ED, Wein AJ, editors. Campbell's Urology, 8 th ed. Philadelphia: WA Saunders Company; 2005.p.2302-3.
2. Kiss A, Sulya B, Szász AM, Romics I, Kelemen Z, Tóth J et al. Long-term psychological and sexual outcomes of severe penile hypospadias repair. J Sex Med 2011;8:1529-39.
3. Gyftopoulos KI. The efficacy and safety of topical EMLA cream application for minor surgery of the adult penis. Urol Ann 2012;4(3):145-9.
4. Kalkan M, Turkan S, Keretli A, Şahin C, Özcan MF, Altınova S. Comparison of different forms of local anesthetic in cystoscopy: a prospective randomized study. J Clin Anal Med 2013;4(5): 397-9
5. Chhibber AK, Perkins FM, Rabinowitz R, Vogt AW, Hulbert WC. Penile block timing for postoperative analgesia of hypospadias repair in children. J Urol 1997;158:1156-9.
6. Sengezer M, Deveci M, Oztürk S, Bozkurt M, Kurt E, Süer AH. Two in one: patient-controlled epidural analgesia (PCEA) to prevent erection and control pain in adult hypospadias-surgery patients. Br J Plast Surg 2002;55:494-7.
7. Canning DA. Comment on Re: The Cleveland Clinic experience with adult hypospadias patients undergoing repair: their presentation and a new classification system. J Urol 2011;186:2409-10.
8. Senkul T, Karademir K, Işeri Cn, Erden Do, Baykal K, Adayener Cn. Hypospadias in adults. Urology 2002;60:1059-62.
9. Adayener C, Akyol I. Distal hypospadias repair in adults: the results of 97 cases. Urol Int 2006;76:247-51.
10. Ansermino M, Basu R, Vandebeek C, Montgomery C. Nonopioid additives to local anaesthetics for caudal blockade in children: a systematic review. Paediatr Anaesth 2003;13:561-73.
11. Sahin C, Seyhan T. Use of buccal mucosal grafts in hypospadias-crippled adult patients. Ann Plast Surg 2003;50:382-6.
12. Sahin C, Aksoy Y, Ozbey I, Polat O. Outpatient urethrocutaneous fistula repair with local anesthesia in adult patients. Ann Plast Surg 2003;50:378-81.

How to cite this article:

Kalkan M, Turkan S, Şahin C. Repair of Adult Hypospadias Under Local Anesthesia: The Technique and Outcomes. J Clin Anal Med 2015;6(4): 410-3.